

DIAGNOSTICS

Clinical and Laboratory Steps

Carle Foundation Day 2008

Curtis Mitchem, DMD, Mitchem Dental
Jerry Ragle, CDT, Ragle Dental Laboratory

Diagnostics

-Cosmetic dentistry is very prevalent in the public eye today.

-Patients are more informed of their choices and want "the perfect smile."

-This presentation is given as a helpful resource in understanding the clinical and laboratory process of esthetic restorations.

A special thanks to Dawn Hollwedel, CDT for her contribution in the following documented procedures.

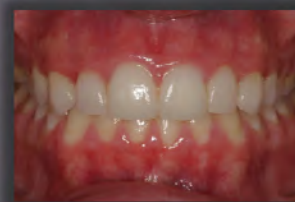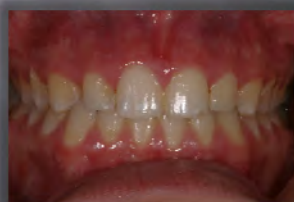What Makes a Good Smile

WHAT ARE THE QUALITIES PERCEIVED BY A PATIENT THAT MAKE A GOOD SMILE?

- | | |
|---|---|
| <ul style="list-style-type: none"> ▣ Ideal Value <ul style="list-style-type: none"> ▪ Smiles that follow curvature of the lip. ▪ Overbite of approximately 2 mm. ▪ Max. central to lateral incisor step 1.4mm ▪ Area of the buccal corridor of 16% ▪ Dental midline centered with philtrum. ▪ No occlusal cant. | <ul style="list-style-type: none"> ▣ Accepted Ranges <ul style="list-style-type: none"> ▪ Smile with minimal curvature. ▪ Overbites of up to 6mm. ▪ Patients accept up to 3mm and many prefer even incisal edges. ▪ A range of 8%-22% and closer to 19% is preferred. ▪ Lower incisor can be 2mm off and not generally noticed. ▪ 3-4mm or approximately 4 degrees. |
|---|---|

JADA October 2008

How do we get from A to B?



Clinical- 1st Appointment

- What is the patient trying to achieve?
- What is it about their smile they are wanting to change?
- What are their expectations?
 - In regards to: color, shape, diastema closure, appearance of the gingiva.
- Discussion of the fees!!!
 - If patient agrees to the treatment and wants to proceed a follow-up appointment is made.

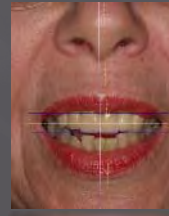Clinical- 2nd Appointment

- Complete Exam
- Full mouth x-rays
- Impressions for pre-op models
- Pre-op photographs
- Discussion about the shade to be used
- Re-discuss patients desired expectations and check that this matches previous notes
- Stick bite or face bow transfer



What is a stick bite and why is it so important?

- A stick bite is a horizontal plane reference taken perpendicular to the long axis of the face and parallel to the interpupillary line .
- A stick bite allows the lab technician to mount the case horizontally to prevent midline canting and to visualize the shape and direction of a natural smile.

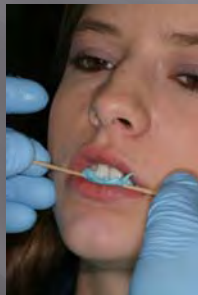
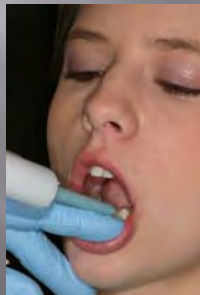
How do I make a stick bite?

•Inject Blue Mousse over the lower incisors allowing material to build up in height as well as outward.

•Have the patient close completely into the material expressing the material forward of the anterior teeth. Roll the stick into the Blue Mousse positioning the stick perpendicular to the patient's face. The stick will be in front of the teeth, just below the upper incisal edges so they are able to occlude naturally.

•Adjust the stick so the stick remains perpendicular to the long axis of the face and parallel to the interpupillary line.



Skull **Basic Technique: Frontal & lateral views**

Basic Anatomy:
The skull radiograph provides information on the bony structures of the skull, including the cranial vault, facial bones, and the base of the skull. The frontal view is used to evaluate the orbits, nasal cavity, maxillary sinuses, and the frontal and ethmoid sinuses. The lateral view is used to evaluate the temporal bone, occipital condyles, and the sphenoid sinus.

Levels of Skull Anatomy:

- 1. Orbit
- 2. Maxilla
- 3. Mandible
- 4. Zygomatic arch
- 5. Sphenoid sinus
- 6. Zygomatic tubercle
- 7. Mandibular condyle
- 8. Occipital condyle

Major landmarks used in Skull radiography

- Medial Sagittal
- Coronal
- Interpupillary

The Medial Sagittal plane
A vertical plane that divides the skull into anterior and posterior halves.

The Coronal plane
A vertical plane that divides the skull into superior and inferior halves.

The Interpupillary plane
A horizontal plane that passes through the pupils of the eyes.

The Auricle plane
A horizontal plane that passes through the external acoustic meatus of the ear.

Major landmarks used in Skull Radiography:

- 1. Orbit
- 2. Maxilla
- 3. Mandible
- 4. Zygomatic arch
- 5. Sphenoid sinus
- 6. Zygomatic tubercle
- 7. Mandibular condyle
- 8. Occipital condyle

The Anthropological Line:
The horizontal "Frankfort" reference line is defined as the upper border of the external acoustic meatus (EAM).

The Orbit-Maxilla Line:
The superior border of the maxilla through the upper margin of the eye socket.

The Interpupillary Line:
The line connecting the centers of the pupils at 45 degrees to the median sagittal plane.

The Auricle Line (Ox Diagram):
The horizontal line 45 degrees to the interpupillary line through the center of the external acoustic meatus.

Note: There is a difference of 15 to 25 degrees between the Orbit-Maxilla line and the interpupillary line.

Skull Radiography: Frontal & Lateral Views

Frontal View:
1. Orbit
2. Maxilla
3. Mandible
4. Zygomatic arch
5. Sphenoid sinus
6. Zygomatic tubercle
7. Mandibular condyle
8. Occipital condyle

Lateral View:
1. Orbit
2. Maxilla
3. Mandible
4. Zygomatic arch
5. Sphenoid sinus
6. Zygomatic tubercle
7. Mandibular condyle
8. Occipital condyle

Skull Radiography: Frontal & Lateral Views

Frontal View:
1. Orbit
2. Maxilla
3. Mandible
4. Zygomatic arch
5. Sphenoid sinus
6. Zygomatic tubercle
7. Mandibular condyle
8. Occipital condyle

Lateral View:
1. Orbit
2. Maxilla
3. Mandible
4. Zygomatic arch
5. Sphenoid sinus
6. Zygomatic tubercle
7. Mandibular condyle
8. Occipital condyle

<http://www.e-radiography.net/technique/skull/basics.htm>

Skull **Basic Technique: Frontal & lateral views**

Basic Anatomy:
The skull radiograph provides information on the bony structures of the skull, including the cranial vault, facial bones, and the base of the skull. The frontal view is used to evaluate the orbits, nasal cavity, maxillary sinuses, and the frontal and ethmoid sinuses. The lateral view is used to evaluate the temporal bone, occipital condyles, and the sphenoid sinus.

Levels of Skull Anatomy:

- 1. Orbit
- 2. Maxilla
- 3. Mandible
- 4. Zygomatic arch
- 5. Sphenoid sinus
- 6. Zygomatic tubercle
- 7. Mandibular condyle
- 8. Occipital condyle

Major landmarks used in Skull radiography

- Medial Sagittal
- Coronal
- Interpupillary

The Medial Sagittal plane
A vertical plane that divides the skull into anterior and posterior halves.

The Coronal plane
A vertical plane that divides the skull into superior and inferior halves.

The Interpupillary plane
A horizontal plane that passes through the pupils of the eyes.

The Auricle plane
A horizontal plane that passes through the external acoustic meatus of the ear.

Major landmarks used in Skull Radiography:

- 1. Orbit
- 2. Maxilla
- 3. Mandible
- 4. Zygomatic arch
- 5. Sphenoid sinus
- 6. Zygomatic tubercle
- 7. Mandibular condyle
- 8. Occipital condyle

The Anthropological Line:
The horizontal "Frankfort" reference line is defined as the upper border of the external acoustic meatus (EAM).

The Orbit-Maxilla Line:
The superior border of the maxilla through the upper margin of the eye socket.

The Interpupillary Line:
The line connecting the centers of the pupils at 45 degrees to the median sagittal plane.

The Auricle Line (Ox Diagram):
The horizontal line 45 degrees to the interpupillary line through the center of the external acoustic meatus.

Note: There is a difference of 15 to 25 degrees between the Orbit-Maxilla line and the interpupillary line.

Skull Radiography: Frontal & Lateral Views

Frontal View:
1. Orbit
2. Maxilla
3. Mandible
4. Zygomatic arch
5. Sphenoid sinus
6. Zygomatic tubercle
7. Mandibular condyle
8. Occipital condyle

Lateral View:
1. Orbit
2. Maxilla
3. Mandible
4. Zygomatic arch
5. Sphenoid sinus
6. Zygomatic tubercle
7. Mandibular condyle
8. Occipital condyle

Skull Radiography: Frontal & Lateral Views

Frontal View:
1. Orbit
2. Maxilla
3. Mandible
4. Zygomatic arch
5. Sphenoid sinus
6. Zygomatic tubercle
7. Mandibular condyle
8. Occipital condyle

Lateral View:
1. Orbit
2. Maxilla
3. Mandible
4. Zygomatic arch
5. Sphenoid sinus
6. Zygomatic tubercle
7. Mandibular condyle
8. Occipital condyle

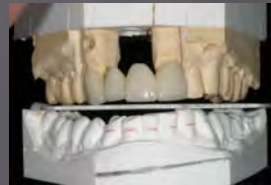
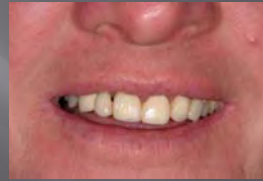Interpupillary

<http://www.e-radiography.net/technique/skull/basics.htm>

How is the stick bite used?

-The stick bite then transfers the patients same plane of orientation to the articulated casts.

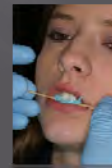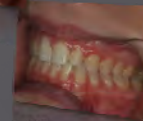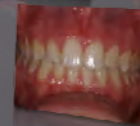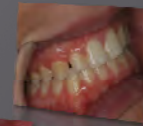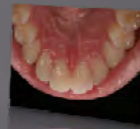*This is very important in canted smile lines.



Clinical- 2nd Appointment

□ Summary:

- Clinical exam and x-rays
- Discuss expectations with patient.
- Take pre-op photos
 - Full Facial
 - Retracted Close-up
 - Side views if needed
- Take Pre-op impressions of the upper and lower arches.
- Stick bite.



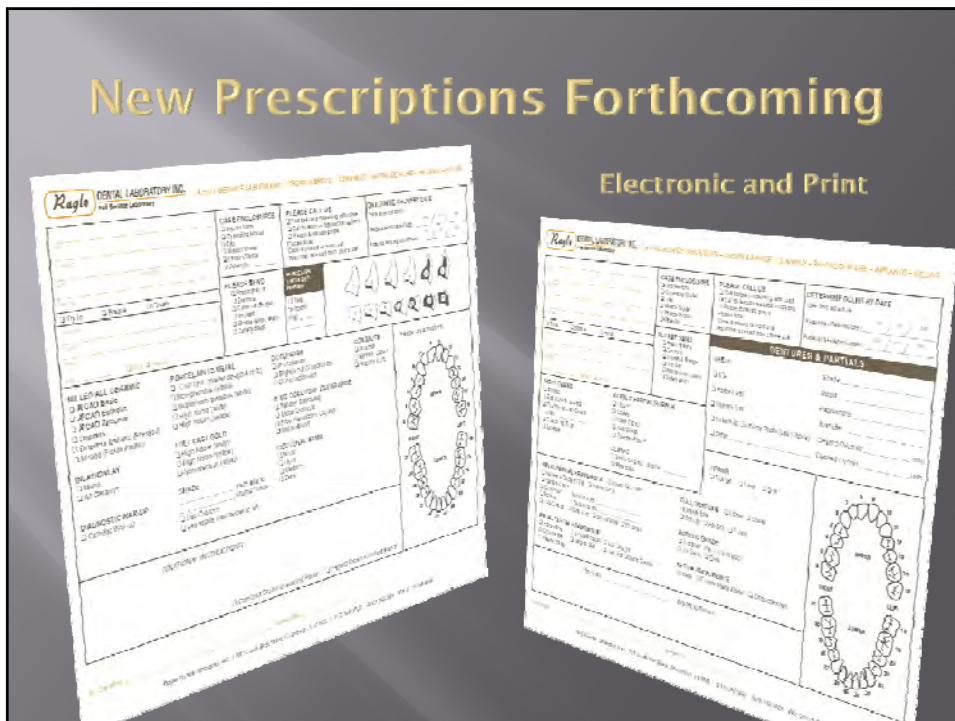
Note: do not prepare teeth at this time

Clinical - to Lab Prep

- The following is prepared for lab pick-up:
 - Pre-op impressions of the upper and lower arches
 - or pre-operative models
 - Stick bite
 - Pictures of the patient before
 - Pictures of desired esthetics
 - Prescription noting specifics of the case

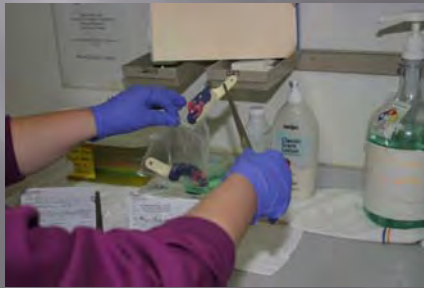New Prescriptions Forthcoming

Electronic and Print



Laboratory- Day of receipt

- ❑ The office receives the case and goes through the disinfection process.
- ❑ Case Entry personnel read through the prescription and go through their check list. If anything is missing from the prescription or the case they immediately call the doctor's office before proceeding. Case is placed on hold if all items are not received.



ESTHETIC DETAILS	
Shading	
<input type="checkbox"/> Enclosed separate Shade Diagram sheet	
Study Model(s) Enclosed	
Follow Existing Prescription	<input type="checkbox"/> Yes <input type="checkbox"/> No
Follow Temporary	<input type="checkbox"/> Yes <input type="checkbox"/> No
Changes Needed _____	
<input type="checkbox"/> Denture Mold	
Specialist _____	
Expectations	
Esthetics _____	
Function _____	
<input type="checkbox"/> Centric Occlusion <input type="checkbox"/> Light Occlusion <input type="checkbox"/> No Occlusion	
<input type="checkbox"/> Opposing Retard <input type="checkbox"/> Opposing Retard <input type="checkbox"/> Other _____	
Future Treatment Planning _____	
Approved by Case Author <input type="checkbox"/> Yes <input type="checkbox"/> No	
<input type="checkbox"/> Please Note <input type="checkbox"/> Please Call	
<input type="checkbox"/> Margins <input type="checkbox"/> Impression <input type="checkbox"/> Other _____	

Laboratory- Day 1

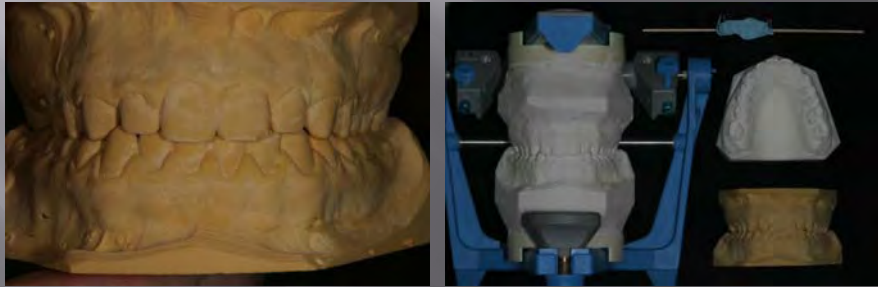
- ❑ Pour up two (2) sets of the new impression in white stone or duplicate if already sent poured.
- ❑ Articulate 1st set using the provided stick bite.
- ❑ Articulate 2nd set alternating models so all mountings are interchangeable.
- ❑ Pour additional working model for prep-guide.



Laboratory- Day 1

Pour up any additional impressions like pre-op's. Do not use doctors models as working models.

This is everything needed to send to the waxing department.



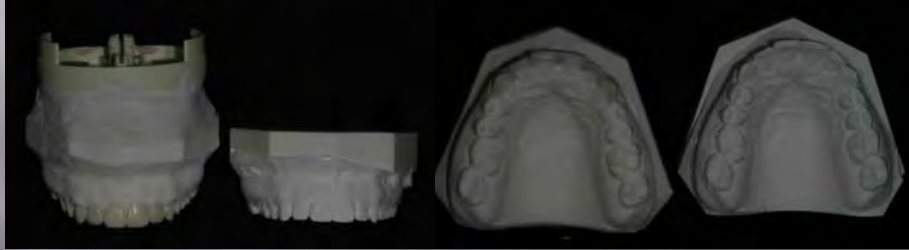
Laboratory- Day 2

The diagnostic wax up is completed following the desired esthetic direction received from the information supplied.



Laboratory- Day 3

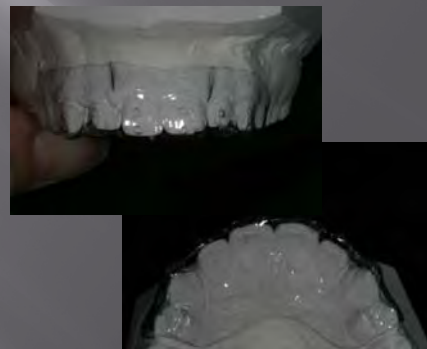Duplicate in stone the diagnostic wax-up.



Laboratory- Day 3

A clear matrix is made from the duplicated diagnostic wax-up model for the prep guide

Placing this matrix on the duplicated pre-op model will show specific areas of needed reduction

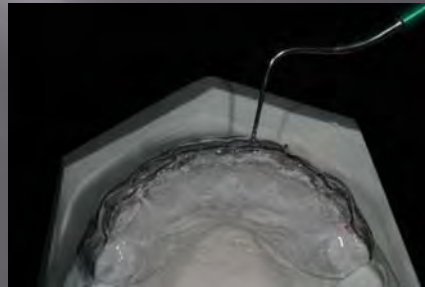

Laboratory- Day 3

Prep model to required restorative depth to assess any possible inconsistencies within the wax-up.

Needed Depths

- Empress Veneer = 1mm
- PFM and All-ceramic Full crowns = 1.5 mm



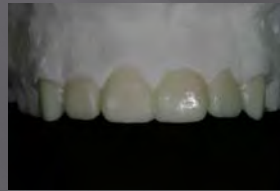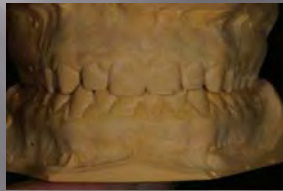Laboratory- Day 4

- Send the case to the doctor for approval and/or changes.
- The case should include the following:
 - The original models
 - Diagnostic Wax-up
 - Duplicate of the diagnostic wax-up
 - Prep guide (clear matrix)
 - Prep guide model
 - Stick bite
 - Any notes from the technician



Clinical- 3rd Appointment

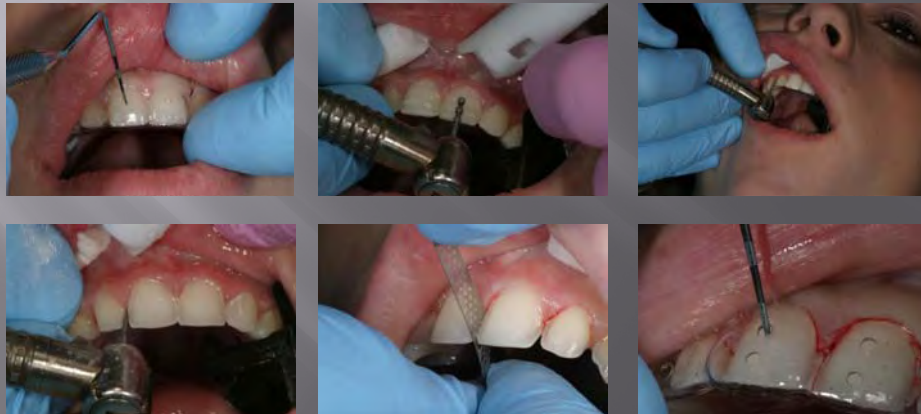- ▣ Show patient the diagnostic wax-up and compare to original models.
- ▣ Discuss the differences and confirm with patient that we have met their expectations.
 - ▣ Length, Rotation, Shape, etc.



Clinical- 3rd Appointment

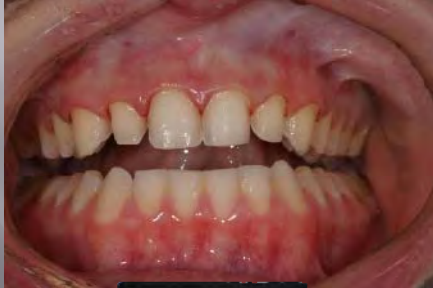Prep-unless wax-up changes were requested

Prepare teeth using the prep guide.



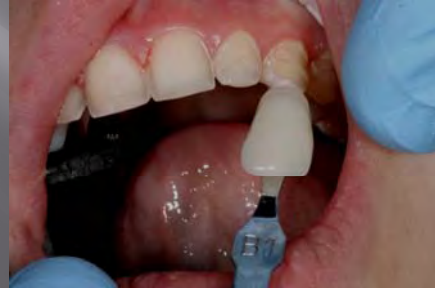Clinical- 3rd Appointment

Fully Prepped




Stump Shade Taken

**Caution- do not allow teeth to become dehydrated. This will result in an inaccurate shade*



What is a stump shade?

- After the tooth is prepped, a shade is taken of the prepared area (*aka the stump*) using:
 - New- IPS Natural Die Material Guide ND1-ND9
 - Original-IPS Empress 2 Stumpmaterial Guide St1-St9

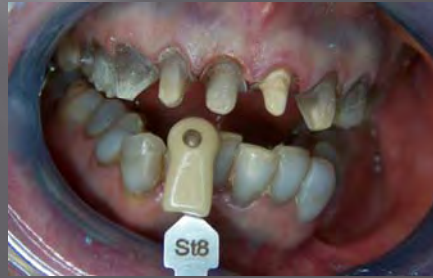
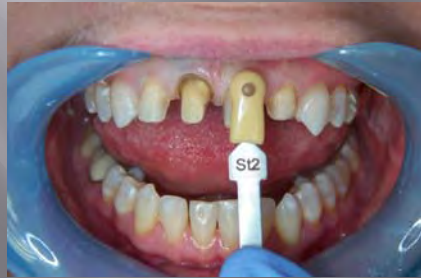
**Guides are available from Ivoclar or Ragle Lab for \$60*

What is a stump shade?

Knowing the stump shade is essential to the lab so they can compensate for it in the final restoration.

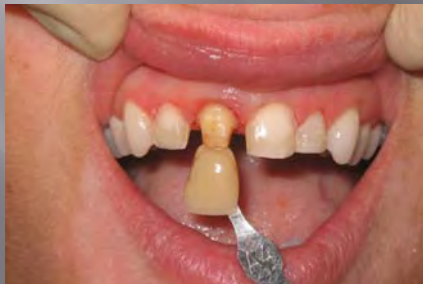A dark stump can throw off the final shade if not accounted for.



What is a stump shade?

Many dentists take the stump shade using the Vita Lumin shade guide.

The stump shades correspond, but are the same color throughout. It is more accurate to use the stump die material guides.

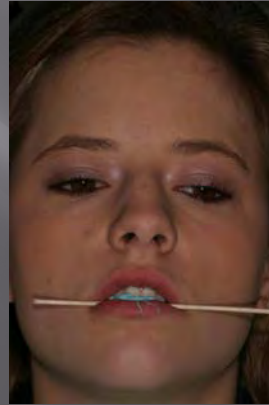
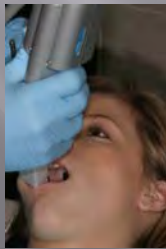

Clinical- 3rd Appointment

Final impression of fully prepared teeth.

**The Itero digital impression system was used in this case.*

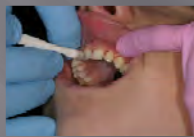A new stick bite is taken.



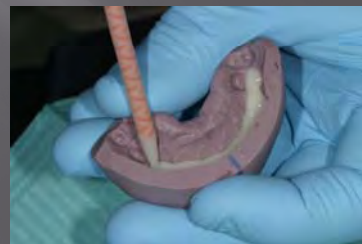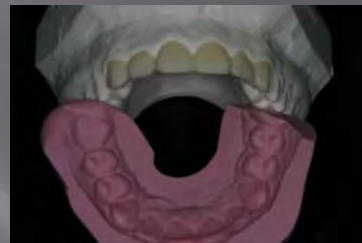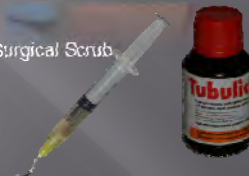
Clinical- 3rd Appointment

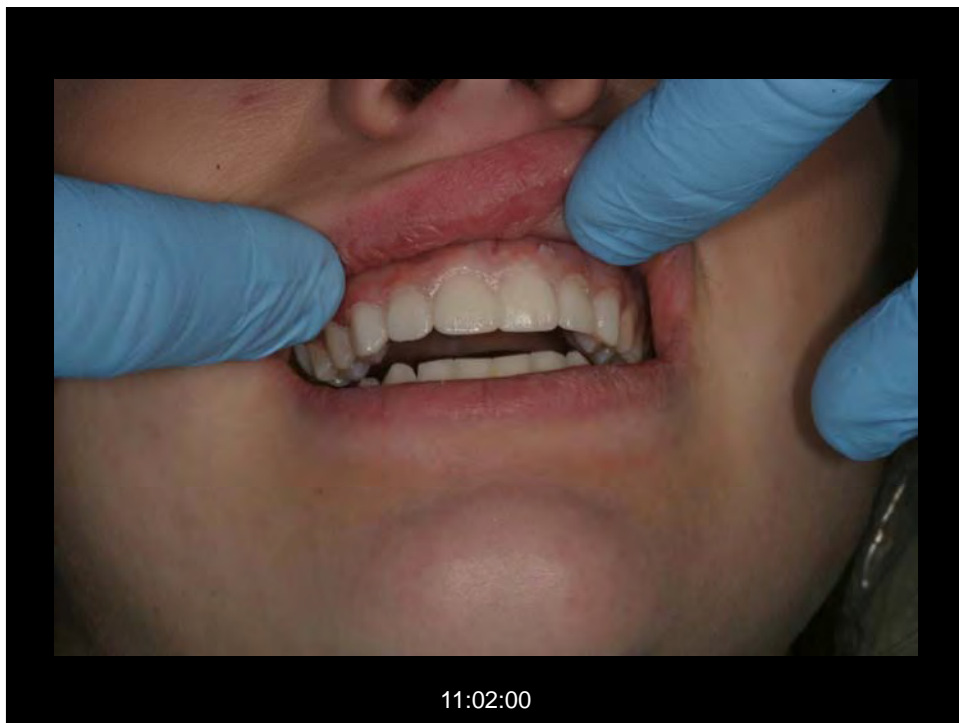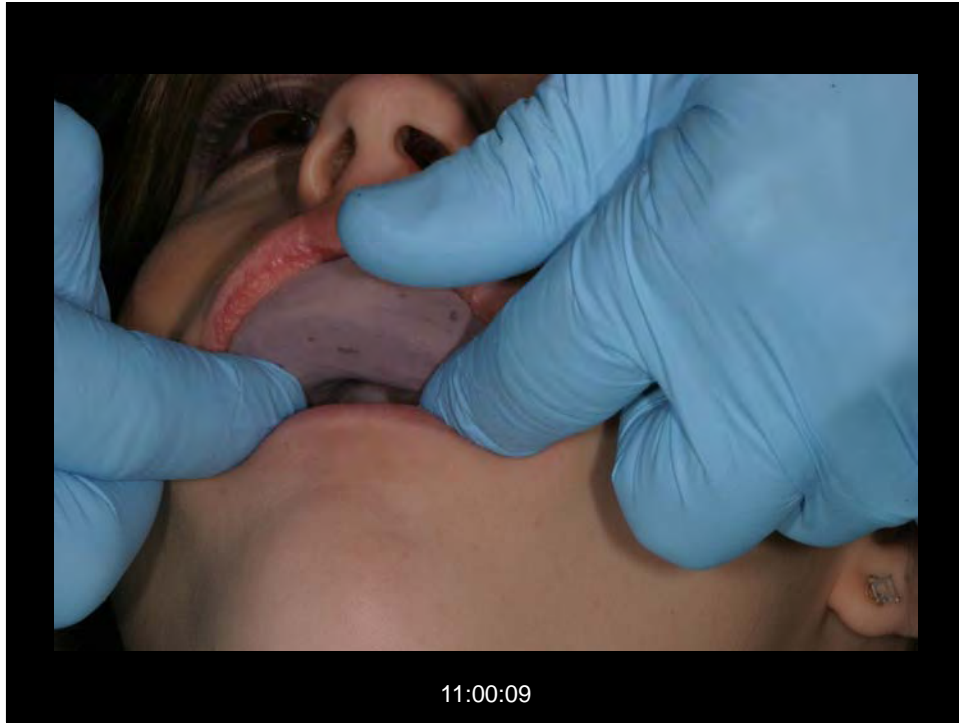□ Temporization

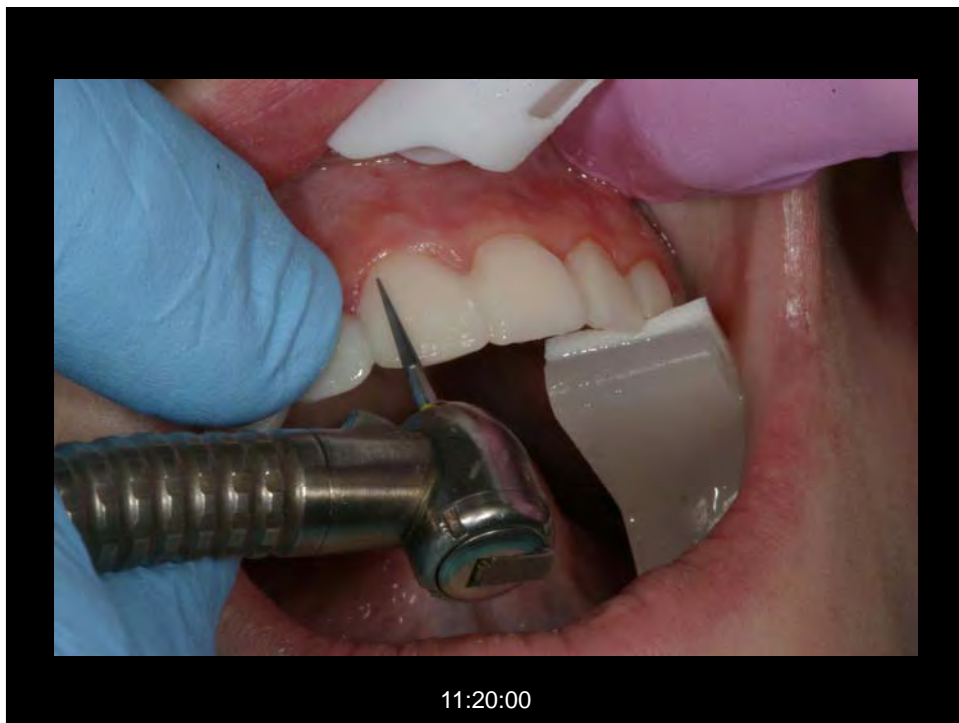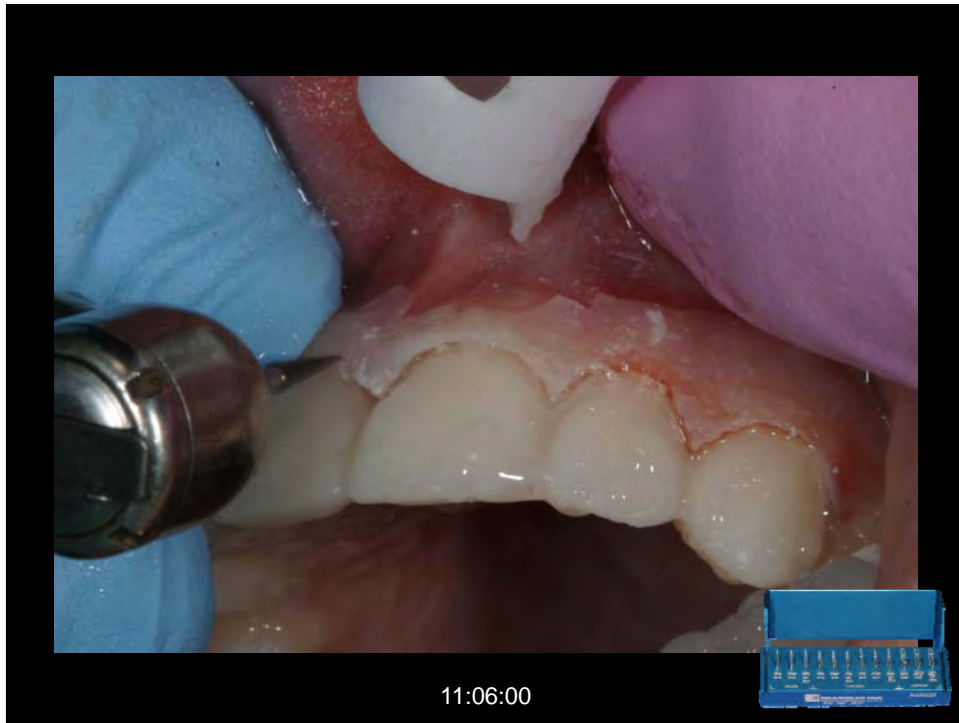- Take a putty matrix of the wax-up.
- Clean Preps
- Inject temporary material into matrix.

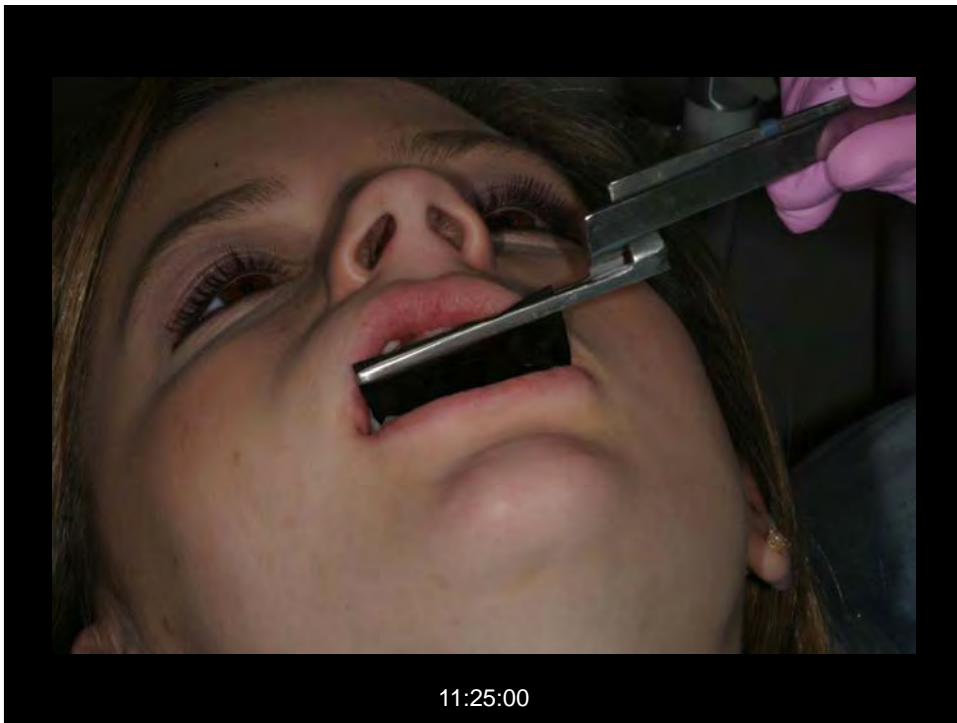
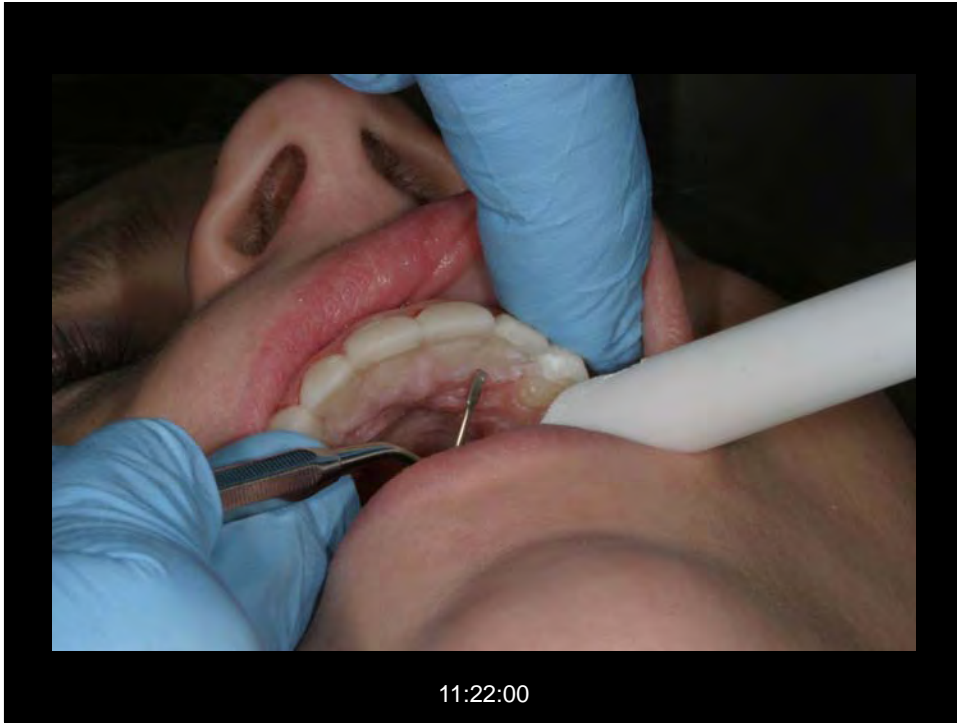


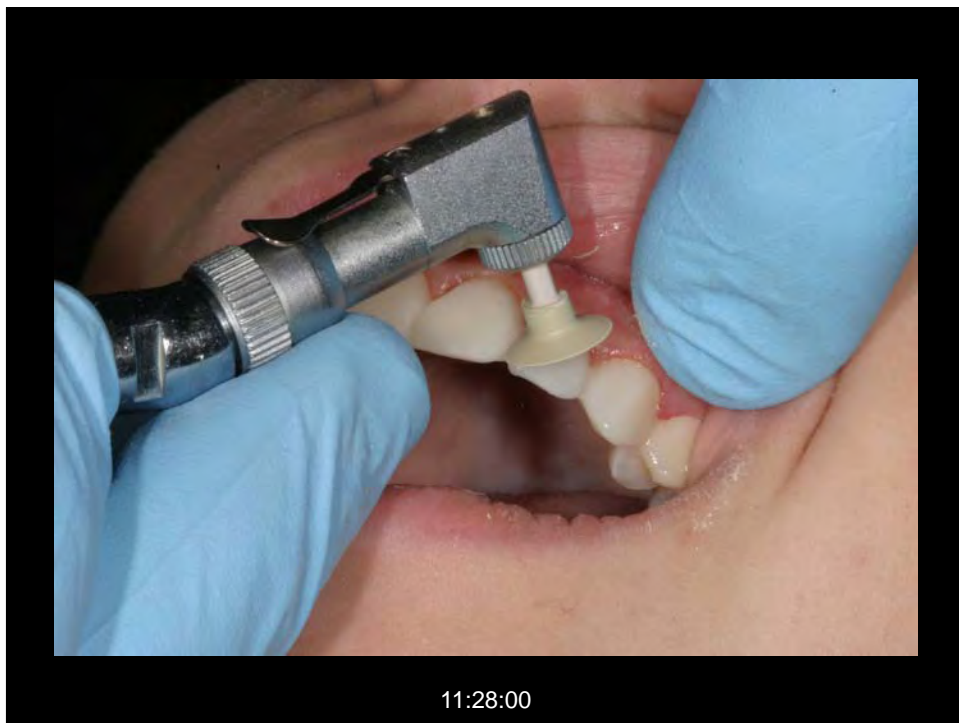
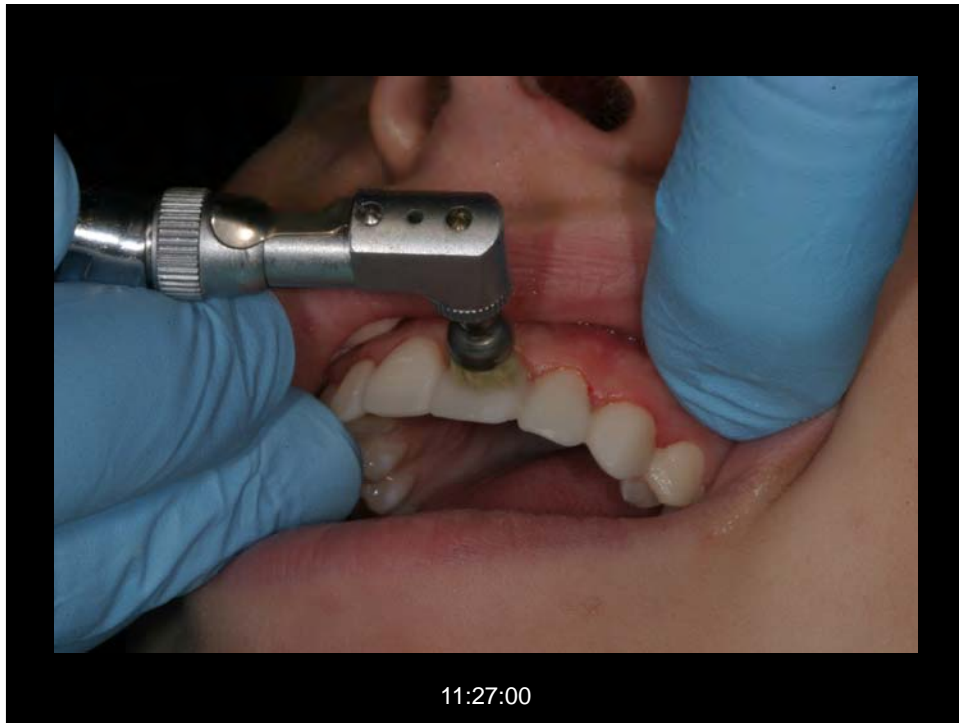Surgical Scrub

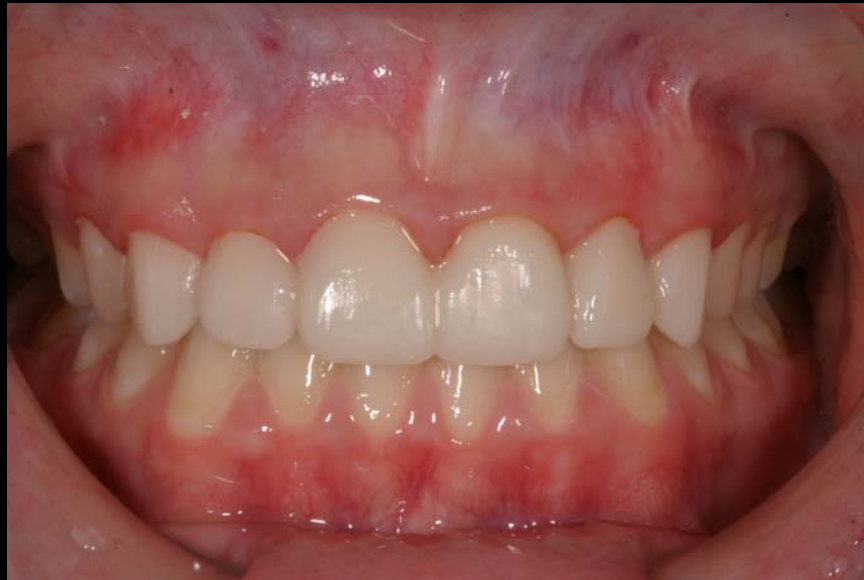







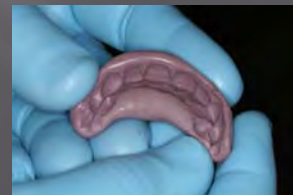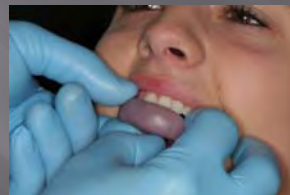
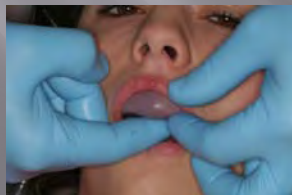
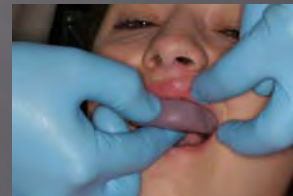
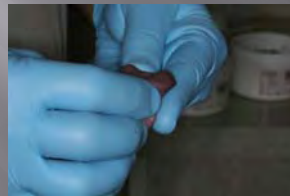




11.31.55

Capturing Final Temp

Impression material or putty can be used



Beautiful temporaries!











**If using a light cure acrylic, inject the temporization material into a clear plastic matrix and light cure.*

Clinical- 3rd Appointment

□ Summary:

- Discuss changes, if any, that were made to the wax-up.
- Prepare teeth.
- Take stump shade.
- Create temporaries from the wax-up and adjust as needed.
- Take an impression of the temporaries if changes were made or putty matrix.
- Send the laboratory all the materials and information to fabricate final restorations.

Clinical to Laboratory

- The following is prepared for laboratory pick- up:
 - New final impression
 - New stick bite 
 - Impression of the temporaries with adjustments made 
 - Original Diagnostic Wax-up 
 - Any pre-operative models 
 - Prescription noting any changes to be made. 
 - Pictures of the patient before treatment 
 - Pictures of desired esthetics.  

Laboratory- Day of receipt

- The office receives the case and goes through the disinfection process.
- Case Entry personnel read through the prescription and go through their check list. If anything is missing from the prescription or the case they immediately call the doctor's office before proceeding. Case is placed on hold if all items are not received.




ESTHETIC DETAILS	
Shading	
<input type="checkbox"/> Enclosed separate Shade Diagram sheet	
Steady Modeling Enclosed	<input type="checkbox"/> Yes <input type="checkbox"/> No
Follow Existing Prescription	<input type="checkbox"/> Yes <input type="checkbox"/> No
Follow Temporary	<input type="checkbox"/> Yes <input type="checkbox"/> No
Changes Requested	
<input type="checkbox"/> Denture Mold	
Selected _____	
Expectations	
Esthetics _____	
Function _____	
<input type="checkbox"/> Centric Occlusion <input type="checkbox"/> Light Occlusion <input type="checkbox"/> No Occlusion	
<input type="checkbox"/> Opposing Retent <input type="checkbox"/> Retent <input type="checkbox"/> Retent	
Future Treatment Planning _____	
Prepared for Lab pickup <input type="checkbox"/> No <input type="checkbox"/> Yes	
<input type="checkbox"/> Please Note <input type="checkbox"/> Please Call	
<input type="checkbox"/> Margins <input type="checkbox"/> Impression <input type="checkbox"/> Other	

Laboratory– Day 1

- Pour new final impression twice.
 - One (1) full solid model with base and die spaced for wax injection.
 - One (1) poured full, pinned and trimmed for margins.
 - Pour impression of the temporaries (if sent).

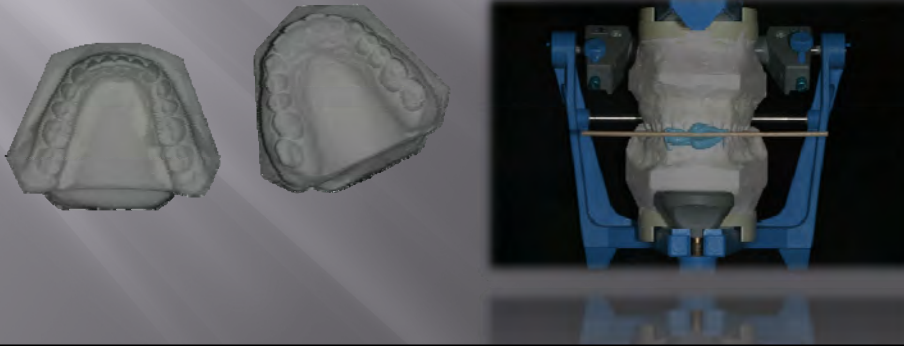
Laboratory– Day 1



- Check the prepared teeth against the prep guide. If proper reduction has not been given call the doctor.
 - *Crucial step-if not reduced properly diagnostics were pointless and a waste of everyone's time and money, not to mention the possible dissatisfaction of the patient and the reworking of the case!*
 - Option 1 would be to re-prep.
 - Option 2 would be to reduce and supply reduction copings.
 - Option 3 would be to pay for the case again when the patient is dissatisfied.

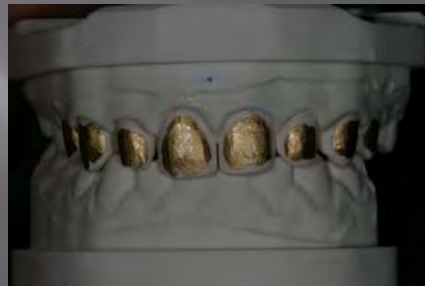Laboratory- Day 1

- Articulate models using the stick bite so all models interchange with each other.



Digital Impression

- Cadent iTero model received.
- Paint die spacer on the dies.
- No additional models are needed for:
 - Wax injection
 - Die trimming
 - Solid to fit back to
 - Tissue model



Digital Impression

- If you are not considering the purchase of a digital impression system you are losing out increasing your practice by an efficiency of 17% as well as a 17% increase over current revenue.


What does 17% more efficient equate to?
 -in a 32 hour work week-
 -over the course of one year-

=

254 hours of unused chair time!

Cadent iTero vs. Conventional

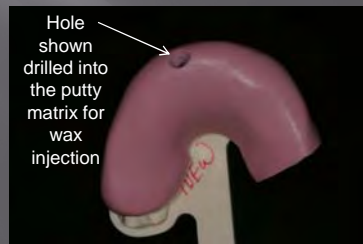
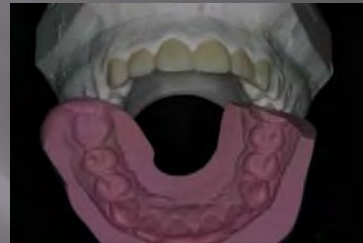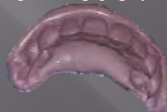
○ Comparison Calculation:

	Hr.	Min.	Average Minutes		
			26	32	
Chairtime	\$500	\$8.33	\$217	\$267	
Units	12 mo.	550	\$119,167	\$146,667	
	Wk.	11			
Material	80%	single units	\$10	\$12	\$4,840
iTero Scan	80%	single units	(\$25)	(\$25)	(\$11,000)
					(\$6,160)
Labor Savings			\$132,917		
Less Material			(\$6,160)		
Total Savings			\$126,757	254 hrs/8 wks/17%	

Laboratory- Day 2

Waxing Department

1. If no temp model is provided make any necessary changes to the diagnostic wax-up.
2. Make a putty matrix of the new temp model either stone or iTero.
3. Use supplied putty matrix in lieu of model.

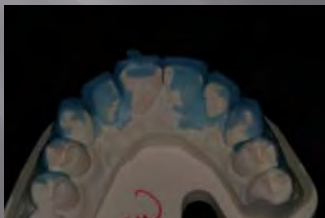

Laboratory- Day 2

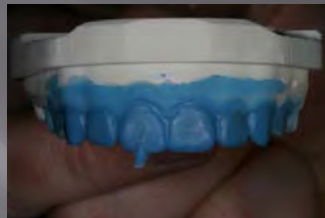Putty matrix filled with wax from wax injector



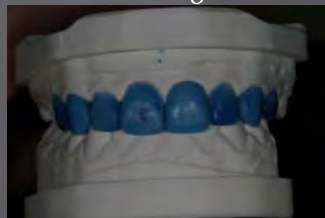
Remove Flash, fill any voids, make final corrections



Removal of the putty matrix



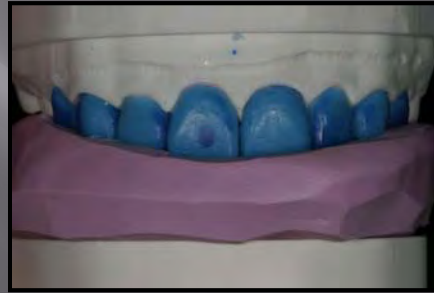Cut apart, finalize contacts, seal margins



Laboratory- Day 2

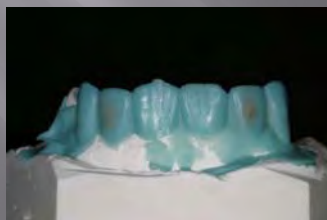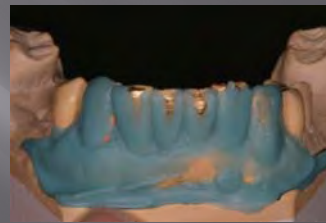CRITICAL STEP

- ▣ The final injected wax-up is checked against the incisal matrix taken from temp model to ensure exact replication.
 - ▣ If temp model is not available the incisal matrix of the diagnostic wax-up is used.



Prep Guide Not Followed

When the prep guide is not followed all thin areas need additional wax added thereby changing all previously approved diagnostics.



Laboratory- Day 3

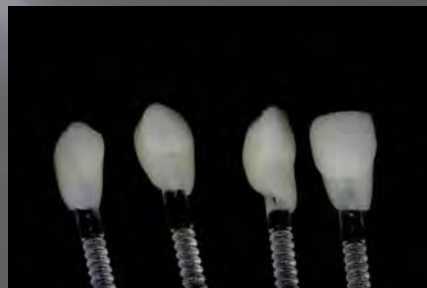Sprue, Invest, and Press.



Laboratory- Day 3

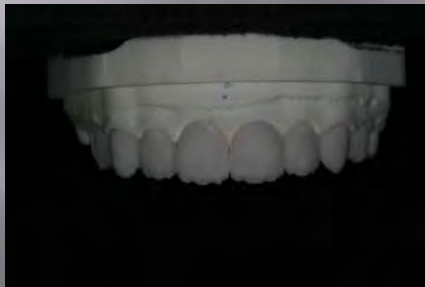
Fit restorations to working model.

Make stump die.

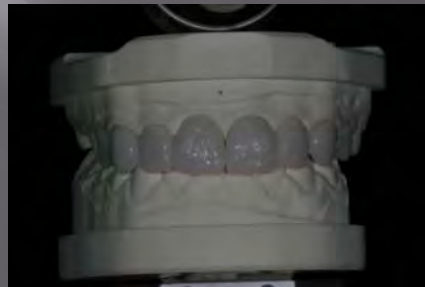

Laboratory- Day 4

Cutback facings to make room for incisal porcelain

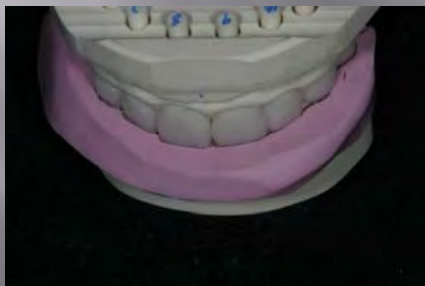

Add incisal porcelain

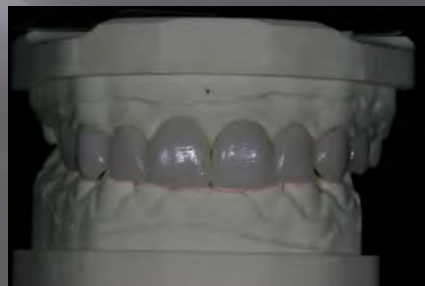

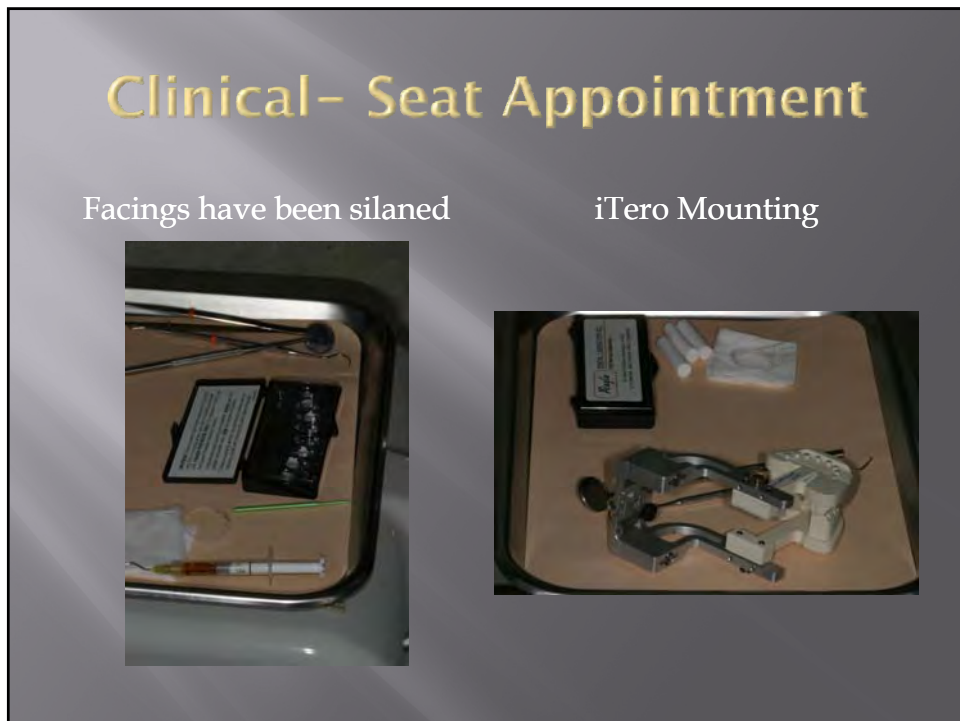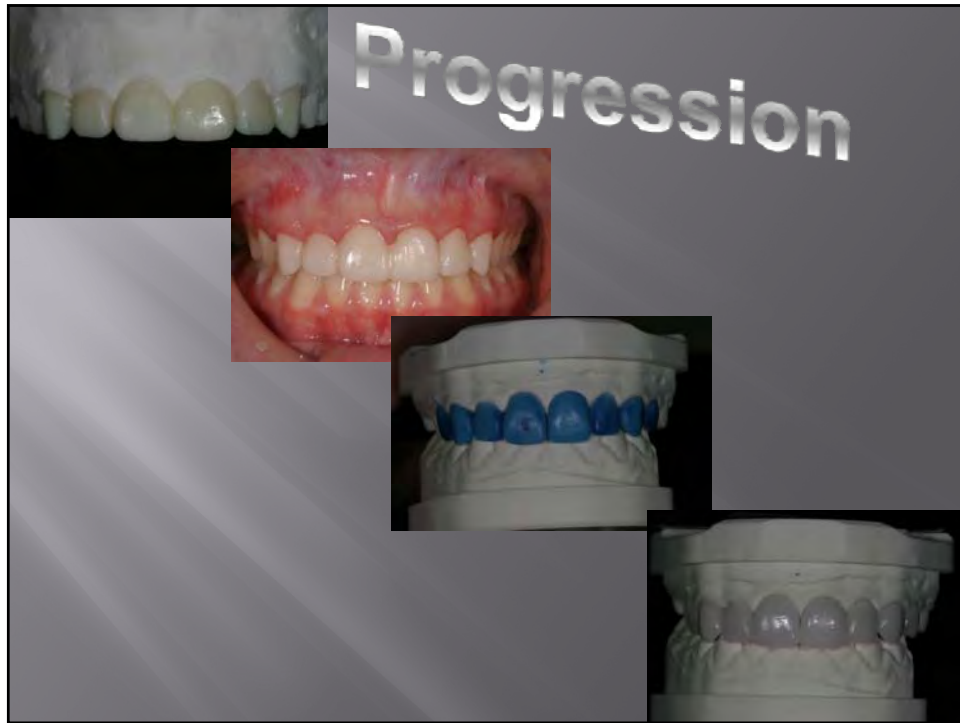Laboratory- Day 5

Use the putty incisal matrix to check the addition of the incisal porcelain to ensure exact replication



Finish Contouring, Stain and glaze, prepare for delivery

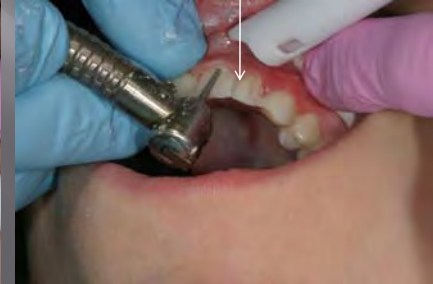
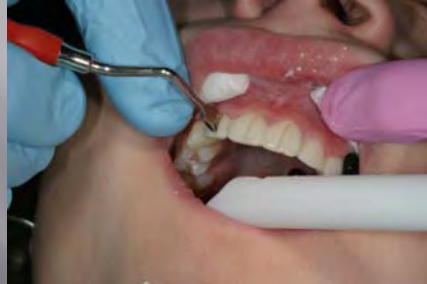


Clinical- Seat Appointment

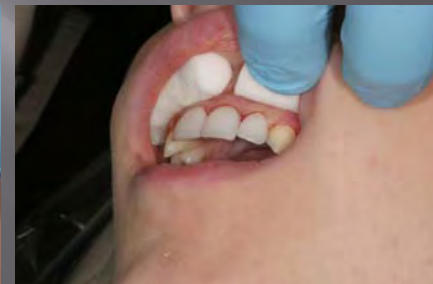
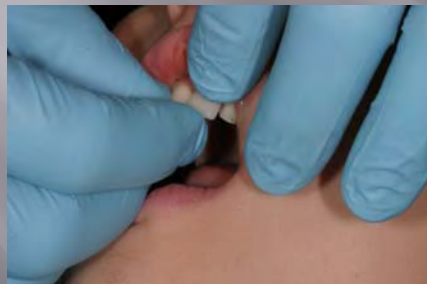Remove Temporaries

You will come off NOW!!!



Clinical- Seat Appointment

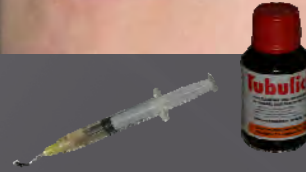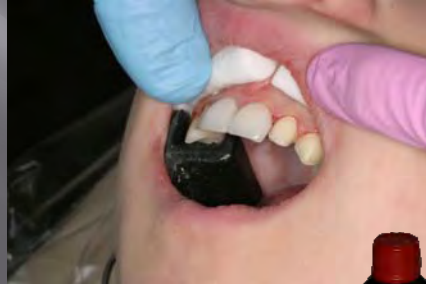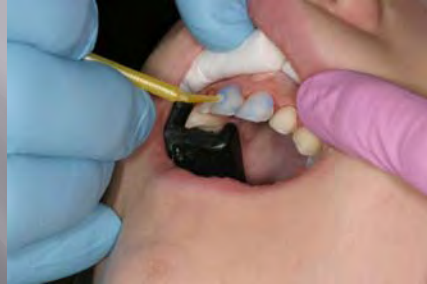Try in Restorations



Clinical- Seat Appointment

Etch 8 & 9

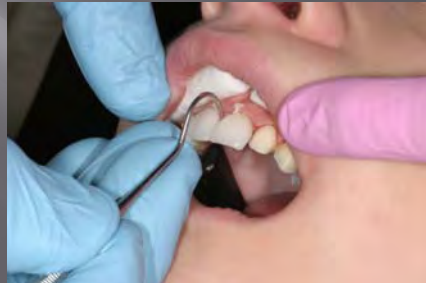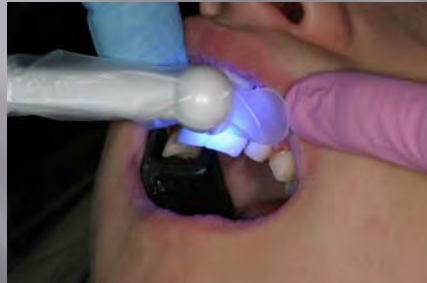Seat 8 & 9 First



Clinical- Seat Appointment

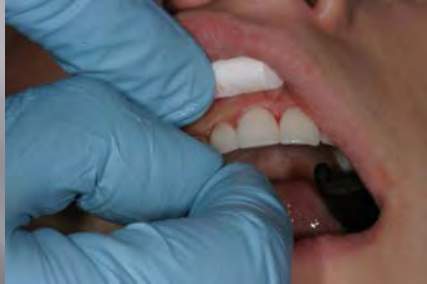Light cure

Clean up

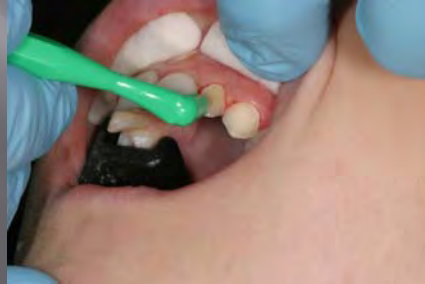

Clinical- Seat Appointment

Patient Right

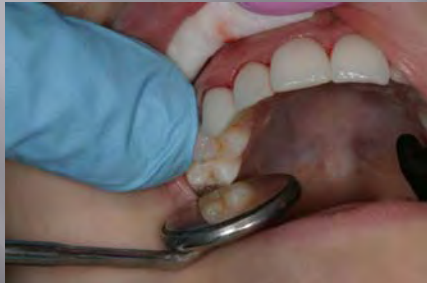

Patient Left

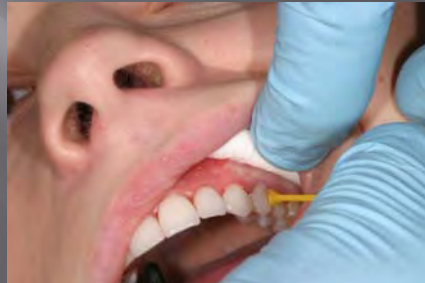

Clinical- Seat Appointment

Patient Right

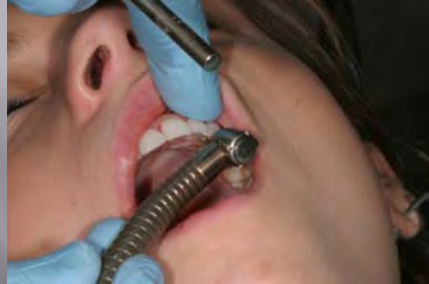

Patient Left

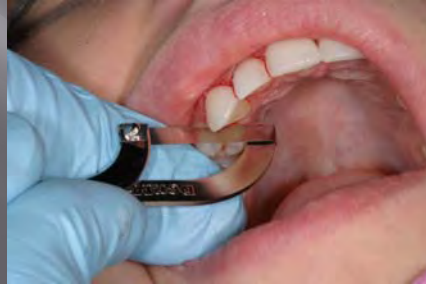

Clinical- Seat Appointment

Bite Adjustment

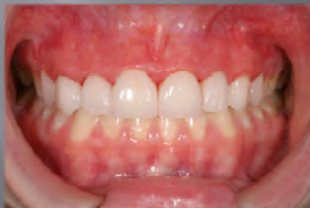
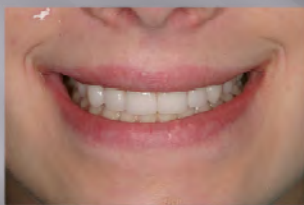
Contact Check

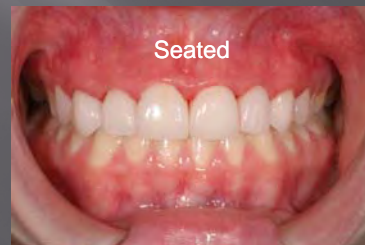
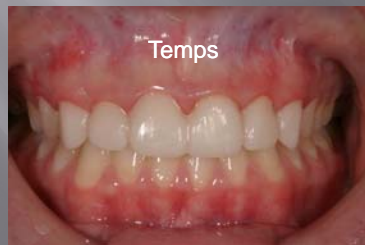
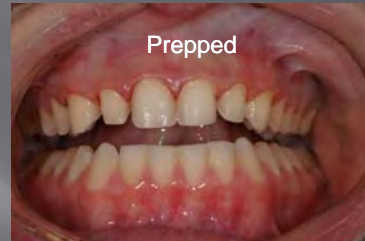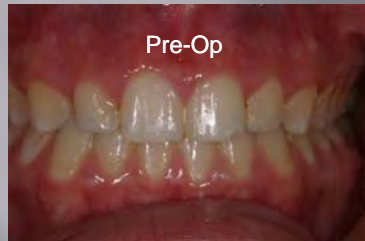Clinical- Seat Appointment

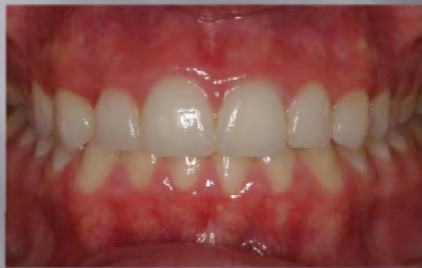A HAPPY PATIENT!



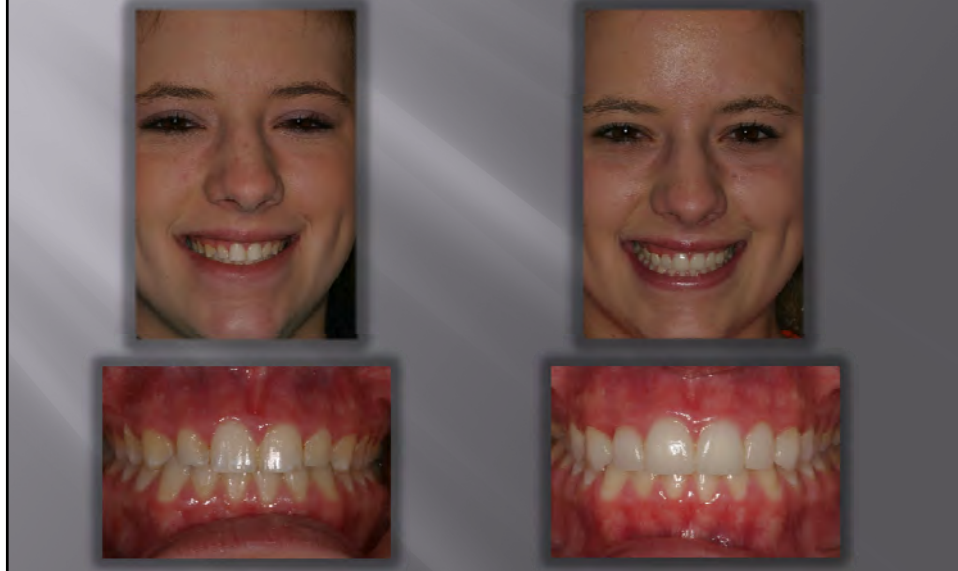Progression



9 Month Post-Op



How did we get from A to B?



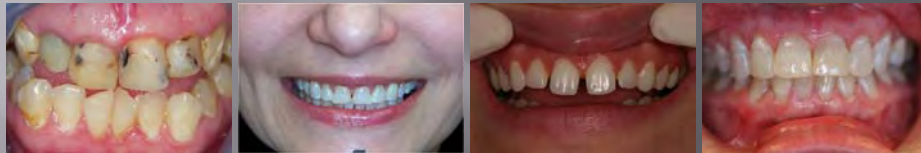
Answer

- Listening to the patient.
 - Concerns, needs, wants, and expectations

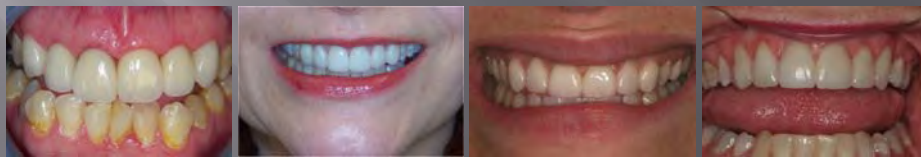
- Determining the practicality through diagnostics in making sure the desired expectation could be met.

Other Cases

BEFORE



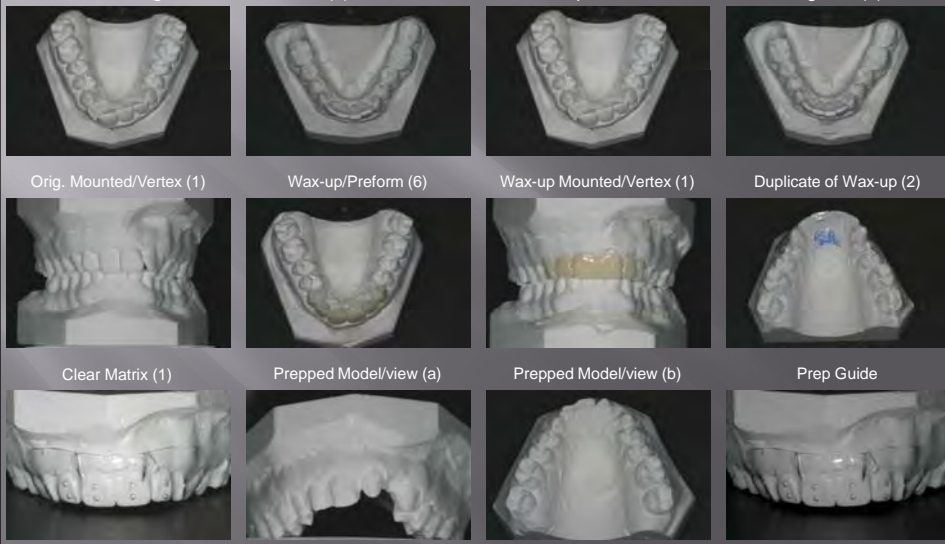
AFTER



Diagnostic Service

Original Models Poured (2)

Duplicates Models Made of Originals (2)



www.raglelab.com/education/techinfo.html

Literature

Diagnostic Service

Diagnosis Models (Dental) → Diagnostic Models (Dental) → Diagnostic Models (Wax) → Wax-up (Full) → Wax-up (Partial) → Final Wax-up

Diagnostics

Clinical and Laboratory

Dr. Peter Dawson refers to doing a case four times, in your mind, in wax, in plastic and in the final restorative material. It is in the second phase, or wax, when the doctor and technician develop the understanding and plan to make the result a success. Like the old axiom, "if you don't know where you're going, any road will take you there", the waxing phase ensures you know where you're going.

- Analysis of natural anterior teeth.
- Plan proper treatment planning and case design.
- Acquire guidelines for precision anatomical build-up and control with less carving.
- Explore techniques that establish ideal contour, function and detail.
- Learn simplified waxing techniques for speed and accuracy.
- Develop the primary skill needed to create the template for provisional restorations.

Associated Fees

Clinical:

- 1st Primary Impressions
- 2nd Imp
- Wax-up
- Wax-up (Dental)
- Wax-up (Wax)
- Wax-up (Plastic)
- Wax-up (Final)

Laboratory:

- Diagnostic Models (Dental)
- Diagnostic Models (Wax)
- Diagnostic Models (Plastic)
- Diagnostic Models (Final)

Pricing Table Handout

Description	Lab Fees		Diagnostic Units											
			1	2	3	4	5	6	7	8	9	10		
Received Poured Model(s) poured	2	\$ - \$ -	\$ -	\$ -	\$ -	\$ -	\$ -	\$ -	\$ -	\$ -	\$ -	\$ -	\$ -	\$ -
	2	\$ 11.50 \$ 23.00	\$ 23.00	\$ 23.00	\$ 23.00	\$ 23.00	\$ 23.00	\$ 23.00	\$ 23.00	\$ 23.00	\$ 23.00	\$ 23.00	\$ 23.00	\$ 23.00
Duplicate Model(s) Articulation	2	\$ 20.00 \$ 40.00	\$ 40.00	\$ 40.00	\$ 40.00	\$ 40.00	\$ 40.00	\$ 40.00	\$ 40.00	\$ 40.00	\$ 40.00	\$ 40.00	\$ 40.00	\$ 40.00
	1	\$ 13.00 \$ 13.00	\$ 13.00	\$ 13.00	\$ 13.00	\$ 13.00	\$ 13.00	\$ 13.00	\$ 13.00	\$ 13.00	\$ 13.00	\$ 13.00	\$ 13.00	\$ 13.00
Wax-up Preform	1	\$ 22.00 \$ 22.00	\$ 22.00	\$ 44.00	\$ 66.00	\$ 88.00	\$ 110.00	\$ 132.00	\$ 154.00	\$ 176.00	\$ 198.00	\$ 220.00	\$ 242.00	\$ 264.00
Wax-up Hand	1	\$ 33.00 \$ 33.00	\$ 33.00	\$ 66.00	\$ 99.00	\$ 132.00	\$ 165.00	\$ 198.00	\$ 231.00	\$ 264.00	\$ 297.00	\$ 330.00	\$ 363.00	\$ 396.00
Prep-Guide/full	1	\$ 20.00 \$ 20.00	\$ 20.00	\$ 20.00	\$ 20.00	\$ 20.00	\$ 20.00	\$ 20.00	\$ 20.00	\$ 20.00	\$ 20.00	\$ 20.00	\$ 20.00	\$ 20.00
Duplicate original working model	1	\$ 9.00 \$ 9.00	\$ 9.00	\$ 9.00	\$ 9.00	\$ 9.00	\$ 9.00	\$ 9.00	\$ 9.00	\$ 9.00	\$ 9.00	\$ 9.00	\$ 9.00	\$ 9.00
Prepare Model	1	\$ 4.00 \$ 4.00	\$ 4.00	\$ 8.00	\$ 12.00	\$ 16.00	\$ 20.00	\$ 24.00	\$ 28.00	\$ 32.00	\$ 36.00	\$ 40.00	\$ 44.00	\$ 48.00
Prep-Guide/partial	1	\$ 20.00 \$ 20.00	\$ 20.00	\$ 20.00	\$ 20.00	\$ 20.00	\$ 20.00	\$ 20.00	\$ 20.00	\$ 20.00	\$ 20.00	\$ 20.00	\$ 20.00	\$ 20.00
Duplicate wax-up model	1	\$ 9.00 \$ 9.00	\$ 9.00	\$ 9.00	\$ 9.00	\$ 9.00	\$ 9.00	\$ 9.00	\$ 9.00	\$ 9.00	\$ 9.00	\$ 9.00	\$ 9.00	\$ 9.00
Prep-Matrix	1	\$ 9.00 \$ 9.00	\$ 9.00	\$ 9.00	\$ 9.00	\$ 9.00	\$ 9.00	\$ 9.00	\$ 9.00	\$ 9.00	\$ 9.00	\$ 9.00	\$ 9.00	\$ 9.00
Total 1-4		\$ - \$ -	\$ -	\$ -	\$ -	\$ -	\$ -	\$ -	\$ 281.00	\$ -	\$ -	\$ -	\$ -	\$ -



Thank-You

-Contact Info-

Curtis Mitchem, DMD

curtmitchem@hotmail.com

Jerry Ragle, CDT

jragle@raglelab.com